

# The Necessary Personal Oral Hygiene For Prevention of Caries and Periodontoclasia\*

by Charles C. Bass, M.D

Reprinted from  
New Orleans Medical and Surgical Journal  
August, 1948

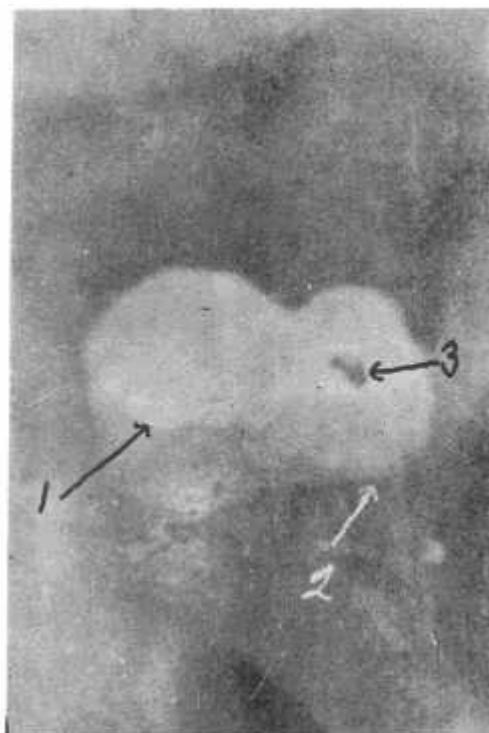
Almost all loss of teeth results from either caries or periodontoclasia. These two diseases can be prevented by the necessary personal oral hygiene. They cannot be prevented in any other way now known. The purpose of this paper is to present the oral hygiene procedure every person must follow in order to entirely prevent these diseases and their consequences, and in order to maintain the state of oral cleanliness most people would like to maintain. The personal oral hygiene procedure here presented as essential has evolved from practical application of already well known fundamental information and more recent additional pertinent information that has been published or is in process of publication (1-4). By intensive microscopic study of extracted teeth, employing technical procedures (1,2,5) not usually employed for this purpose, it has been possible to secure more accurate information regarding the conditions at the locations and in the environment where caries and periodontoclasia begin.

To prevent the occurrence and progress of the lesions of these diseases their early stage must be prevented. The oral hygiene necessary to prevent these diseases, therefore, must effectively meet and counteract the etiological conditions at the locations where the lesions originate.

## Where Caries Begins

Enamel caries begins principally at or about occlusal pits and fissures and at or about the contact area between teeth. The earliest lesion consists of a "white spot" of "chalky," partially decalcified enamel. If the conditions are prolonged the lesion extends in area and depth and finally this fragile, partially decalcified enamel breaks down producing a cavity—the advanced stage of caries. The cavity, if large enough, usually can be diagnosed by the dentist but most of the earlier stage lesions cannot be recognized, except upon extracted teeth.

Some idea of the frequency and extent of these early stage lesions can be gained by very simple procedure, even without any microscopic laboratory equipment or experience. All that is necessary is to place extracted teeth (preferably from persons under 20 years of age) in 10 per cent hydrochloric acid (water 85, formalin 5, HC110) for one minute, then wash and brush with an ordinary toothbrush to remove the loosened cuticle, bacterial film and debris. Any "white spot," early stage caries lesions present can be seen satisfactorily (Figure 1 ) with the unaided eye.

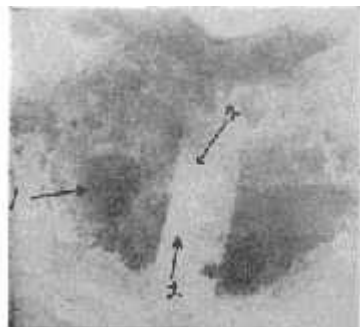


*Fig. 1. Tooth from which the cuticle and bacterial film were removed by application of acid and then brushing. Note area of "white spot" (1) chalky enamel (early stage caries) contrasts with normal enamel. Cemento enamel junction (2). Small cavity (3).*

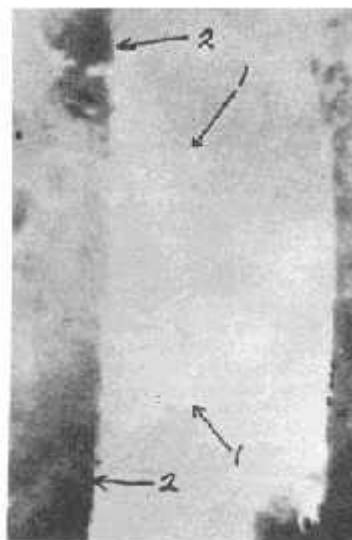
They contrast well with the more transparent normal enamel. The contrast is even sharper after the specimen has been allowed to dry. Under magnification, the lesions may be observed and studied better. Ordinary hand lenses are quite helpful. The dissecting microscope is still more helpful in studying such preparations.

It will be observed that some of these partially decalcified areas have more or less brown stain. In most instances these are old lesions which have been inactive for some time, due to changes in the environment conditions which formerly initiated the lesion and promoted activity. A good example is proximal lesions on a tooth where the contacting tooth was lost some time previously. Such inactive lesions are more often found on teeth from people past 25 years of age.

Sometimes a small broken down area (cavity) may be observed in a larger area of partially decalcified enamel which still holds its form. It will be observed that most small to medium size cavities have more or less unbroken chalky enamel about them. (Figures 2, 3).



**Fig. 2** Area on proximal of molar with cavity (1) and chalky enamel (2). Two parallel cuts were made through the cuticle to include the edge of the chalky enamel. Specimen in acid 1 minute, rinsed and then stained with crystal violet. Strip of loose cuticle removed, exposing some of "white spot" area. Clear strip from which cuticle was removed contrasts well with stained cuticle and bacterial film still in place on either side.




**Fig. 3.** Higher magnification of area on Fig. 10, showing chalky enamel extending outward from beneath cuticle on left side which was retained in place.

No cavity ever forms except as a result of breaking down of this earlier stage decalcified enamel. The early stage, partial decalcification, therefore always precedes cavity formation. Prevention of cavity formation and its consequences can be accomplished only by recognition of the etiological conditions at the location where the earlier partial decalcification occurs and by application there of effective measures for preventing or minimizing those conditions.

## The Enamel Cuticle In Relation To The Early Stages of Caries

It has been shown (2) that the enamel cuticle bears an important-relationship to the early stage of caries. The enamel cuticle is an extremely thin keratin-like, transparent membrane covering the entire enamel surface at all times. It is thinner over areas where it is repeatedly worn by functional or other friction than in other areas where it is not exposed to such friction. However it is extremely thin in such areas also. In view of some confusion and conflicting opinion as to the continued presence throughout life of an enamel cuticle, it may be worthwhile to give here a simple procedure whereby anyone who is interested can clarify the matter for himself. Again this can be done without the aid of microscopic laboratory equipment or experience. Place a tooth specimen in the 10 per cent HC1 for one minute; remove gently and dip in water for a moment to reduce the acid; place in 0.5 per cent crystal violet solution (crystal violet 0.5 gm in water 100 cc) for one minute or less; again dip in water to remove excess of stain. Now observe the loosened cuticle with the tooth immersed in a shallow dish of water in which the membrane may be teased off with some suitable delicate instrument (No. 2 or No. 7 Clevdent or S. S. White Explorer) and manipulated in the water. The cuticle itself is slightly stained and the bacterial film upon it is heavily stained. When floating in the water the membranous nature of this material from the surface of the enamel is readily recognized. One who examines a few specimens in this simple way knows, of his own knowledge, that an enamel cuticle is continuously present on teeth. This enamel cuticle is of interest in relation to caries because the bacterial film over the early stage lesion is firmly attached to the cuticle (Figure 4) and because the acid or acids which cause the first partial decalcification there must pass through the intact membrane to reach the enamel.



**Fig. 4.** Section through cuticle and attached bacterial film removed from over early stage caries. Note parallel arrangement of organisms (1) extending from cuticle (2) outward toward surface the pile (3). Acids produced at the surface are carried as if by a wick or sponge through the material down to the cuticle.




**Fig. 5.** Bacterial film material from over early stage caries lesion torn apart, stained, mounted in 50 per cent glycerin and photographed by transmitted light, shows filamentous nature of material.

## Nature of the Bacterial Film Over the Early Stage Lesions

A film or pad of soft bacterial material of variable thickness is present on the surface of the tooth at all areas where it is protected from removal by functional or other friction. It is thickest where it is best protected. Microscopic examination of appropriate preparations of this material ("soft tartar") shows it to be composed entirely of bacteria, usually of many different kinds. (Figure 5). One characteristic of such bacterial material over early stage caries lesions (and elsewhere in most cases) is that it consists mostly of long rod and filamentous forms, one end of which is attached to the cuticle on the tooth. The rods and filaments extend outward, more or less parallel to each other, toward the surface of the pile or pad. At the surface there are the growing ends and fruiting heads of the long forms of which the deeper part of the film is composed (Figures 7, 8, 9); and among these, large numbers of other bacteria of many different kinds.

## Production of Acids At Caries Locations

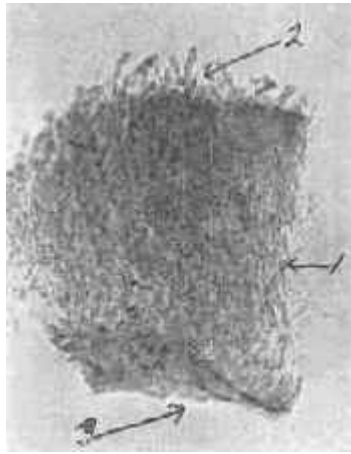
Food, as it is masticated, is thoroughly and heavily inoculated with many different kinds of bacteria in the saliva, derived from all the different locations within the mouth. The bacteria in such heavily inoculated food material lodged and retained upon the constantly present bacterial film pad at favorable locations about teeth, multiply and, through the action of their enzymes, break down the material which serves as their culture media. Many bacteria, when growing in the presence of favorable carbohydrates, produce acids.



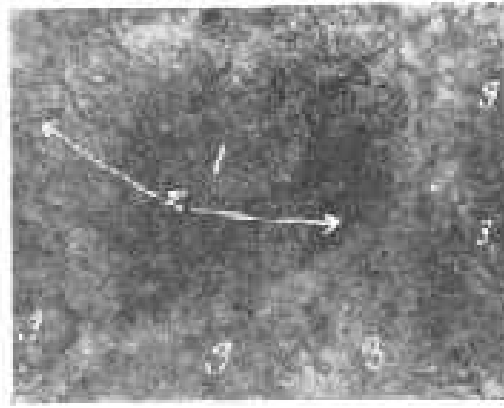
**Fig. 6.** Ground section, unstained, **Fig. 7.** Section cut through compact bacterial film pad through early stage caries showing removed from over white spot caries lesion. Note rods and bacterial film attached to surface of filaments extending outward (2) from the cuticle (1) to tooth and indicating parallel rod which they are firmly attached and (3) fruiting heads of and filamentous organisms (1, 2) *Leptothrix racemosa* projecting at the surface. with growing ends and fruiting heads (3) at the surface of the pile. Photographed by transmitted light which causes the white chalky enamel to appear dark. Note lines of Retzius (4) enamel prisms (5) and feathery edge at deeper part (6).

Such acids produced by bacteria at the surface of the bacterial film or within it, are carried, as if by a sponge or wick, through the film to the cuticle through which they pass to the enamel beneath. If such acids are produced at the particular location in sufficient strength and over sufficient length of time, decalcification of the enamel occurs. This decalcification is only partial, giving rise to the softened "white spot" caries lesion. The enamel is not completely dissolved by such weak acids in the same way as it may be, experimentally, by stronger acids. For instance, the enamel is completely dissolved and disappears (except for some remaining enamel matrix material) from a tooth immersed in 10 per cent HCl for an hour or two. On the other hand the enamel on a similar tooth immersed in 0.15 per cent HCl, even for much longer time, is not dissolved in the same way. Only partial decalcification occurs, similar to the partial decalcification of the "whit spot" caries. The enamel on the tooth becomes softer and may be broken up or crushed like a piece of chalk in much the same way as that of the early stage lesion may be. Anyone interested can confirm this observation by the simple procedure of immersing (suspending) tooth specimens in solutions of acid of the suggested strengths, for several hours (several days for weak acids).

What seems to be the same kind of partial decalcification may be produced experimentally by solutions of organic acids, such, for instance, as lactic acid—the one generally supposed to be the most important in caries production. However, weak solutions of organic acids, such as can be assumed to be formed at caries disposed locations, act very slowly.



**Fig. 8.** Piece of the bacterial film from over early stage caries lesion. Specimen teased off, stained very lightly with safranin and mounted in 50 per cent glycerin for photographing by transmitted light. Note filamentous nature of bacterial material (1) and growing ends and fruiting heads at outer surface (2). Inner surface (3).



**Fig. 9.** Bacterial film pile on surface of tooth over early stage caries ( chalky enamel ) stained lightly with safranin and photographed with incident light. Note mound of *L. racemosa* (1) with some fruiting heads focused around periphery (2). Many more just out of focus.

It is only after long continued exposure to such weak acids experimentally that demonstrable partial decalcification occurs. Likewise it is only after long continued and repeated production of acids by bacterial action, that a caries lesion results. It is very apparent that to prevent early stage caries at any vulnerable place on a tooth, it is necessary to prevent the formation of acids by bacteria growing there\*

## Time Factor In Production of Acids By Bacteria

Some bacteria grow and produce acids much more rapidly than others. However any of them require considerable growing time, under the most favorable conditions, for production of appreciable amounts (or strengths). Perhaps the most familiar example for those who have been medical or dental students is the testing of acid production by pure cultures of different bacteria inoculated into litmus milk. Litmus milk is blue. A tube of such culture media inoculated with a loopful of a pure culture of an acid producing organism and placed in the incubator still remains blue for several hours, usually twelve or fifteen or more. After the necessary incubation time it will be noted that the color is changing to a faint pink and finally, within twenty-four hours or a longer period, to red, indicating production of considerable lactic acid from the sugar in the milk. Stephan and Millers showed that brushing the teeth thoroughly before rinsing with 10 per cent glucose solution eliminated the fall in pH which otherwise would have occurred. They found that in testing plaque material in situ for pH drop following the glucose rinse, subjects who refrained from brushing their teeth for three or four days, thereby insuring a sufficient amount of bacterial material on accessible surfaces, gave most satisfactory results. Therefore a considerable period of time is required for sufficient growth and accumulation of bacteria to occur before much acids can be produced in the presence of carbohydrates.

*\*Note: I am aware of the suggestion, belief or claim by recent authors (6, 7, 8, 9, 10, 11, 12, 13, 14) that caries is, to some extent, a proteolytic process by which the organic material of the enamel is invaded and broken down by the enzymes of proteolytic bacteria and that this is followed or accompanied by disintegration or decalcification of the inorganic material. The personal oral hygiene for prevention herein specified would be equally applicable to such order of events in the caries process.*

However another factor plays an important role in the production of acid, i. e., the amount of inoculum or number of bacteria with which the culture medium is inoculated. If, for instance, a tube of litmus milk is inoculated with say 2 or 3 cc. of rich culture, containing enormous numbers of viable bacteria, instead of the loopful as suggested above, containing relatively only a fraction as many, then we find acidity developing and the color changing within a shorter time, sometimes only a few hours.

Applying the above elementary information to our problem of preventing acid formation and thereby preventing caries, it is evident that removing from about a tooth all food material which may serve as culture media for acid producing bacteria and removing from the same location most of the bacteria, there will be little growth of bacteria

(for lack of culture media) and no production of acid( for lack of fermentable carbohydrates) until food is again lodged at the particular place and sufficient time elapses for bacteria to multiply and produce acid.

Decomposing food material that has been retained and has accumulated about the teeth during the daytime gives the bacteria growing there a good start towards acid production by bedtime. If these conditions are allowed to continue through the night during sleep the most favorable conditions exist for more rapid bacterial growth and production of acids, and their action upon the teeth. As a matter of fact, the caries process progresses principally at night and during sleep. Therefore to prevent the initiation and further progress of caries the teeth must be effectively cleaned of food and accumulated bacterial material at night before retiring. Nothing else will suffice.

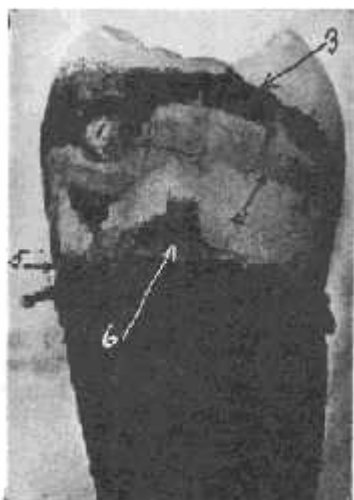## Early Stage Peridontoclasia

Periodontoclasia begins and progresses as a local microscopic disease process. The earliest stage lesions are too small and inaccessible to be recognized except by microscopic examination of suitable sections or other preparations of the tissues involved. What is ordinarily diagnosed clinically as periodontoclasia (pyorrhoea) on the basis of flow of visible amounts of pus, receded periodontal soft tissue, alveolar resorption, pocket formation, loosened drifting teeth, etc., represents, in fact, the far advanced stage and results of a disease that usually has existed and progressed at the particular location for many years. Long previously, there was an earlier stage, actually a beginning, of the same disease about the same tooth. It is this earlier stage against which effective prevention must be directed. Measures for this purpose must be based upon clear understanding of the etiological conditions at the locations where the disease starts and from which the lesions about each tooth advance.

## Relation Of The Enamel Cuticle To Early Stage Lesions

It has been shown that the enamel cuticle bears an important relationship to the early stage of the periodontoclasia lesion. The marginal gingiva normally rests upon the smooth, non-irritating enamel cuticle. Bacteria allowed to grow and accumulate for a long time on the tooth at the gingival margin, tend, in time, to produce microscopic roughness and hardened concretion upon the cuticle. The tendency is for this to increase, not only encroaching upon the gingival margin but extending into the gingival crevices (Figure 10). In time a narrow portion of the free gingiva (the free gingiva is that portion extending occlusalward from the level of the bottom of the crevice) rests against a surface covered with hard concretion and a pack of soft bacterial material. The irritation caused by the presence of this foreign material upon the tooth, where normally smooth, non-irritating cuticle exists, soon causes inflammation; at first only microscopic in extent. Minute and microscopic quantities of inflammatory exudate and pus cells are poured out through the inflamed tissue into the gingival crevice, and these tend to promote the growth of microorganisms and increase of the concretion. As the foreign material on the tooth increases and advances further into the gingival crevice, the soft tissues attached to the tooth are forced back by the accompanying inflammation and ulceration. Gradually and almost imperceptibly a larger and larger portion of the tooth is exposed as the gingival margin moves further away from the occlusal level. The gum "recedes."

Many factors influence the progress of the lesions at different locations about a given tooth, about different teeth in the same individual and in different individuals. For our present purpose of prevention of the disease (lesions) and prevention of further progress of lesions that already exist, it is only necessary to adopt and direct effective measures against the conditions at and within the gingival crevice. The disease process involving the more remote tissues—periodontal membrane, alveolar bone—rapidly subsides as soon as the local lesions consisting of inflamed, suppurating and broken surface of the epithelial tissue of the gum within the crevice, subside and disappear.



**Fig. 10.** Proximal of extracted tooth stained with crystal violet showing biconcave disc of bacterial material surrounding contact area, and heavy film which extended from the gingival border (gingival crevice) occlusalward. Contact point (1). Disc of bacterial film material surrounding contact point (2). Heavy bacterial material on area protected from functional friction (3). Epithelial cells remaining attached to tooth (4). Location of cemento-enamel junction (5). Some epithelial attachment tissue retained on tooth (6).

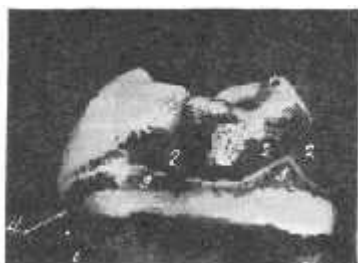From the earliest stage and continuously as the lesion progresses, the tooth surrounded by this concretion and

bacterial material adhering to it within the gingival crevice is, in effect, a foreign body infected with many different kinds of bacteria. It is a suppurating lesion constantly exposed to invasion by any and all of the many different kinds of bacteria within the mouth which are capable of growing in such an environment.

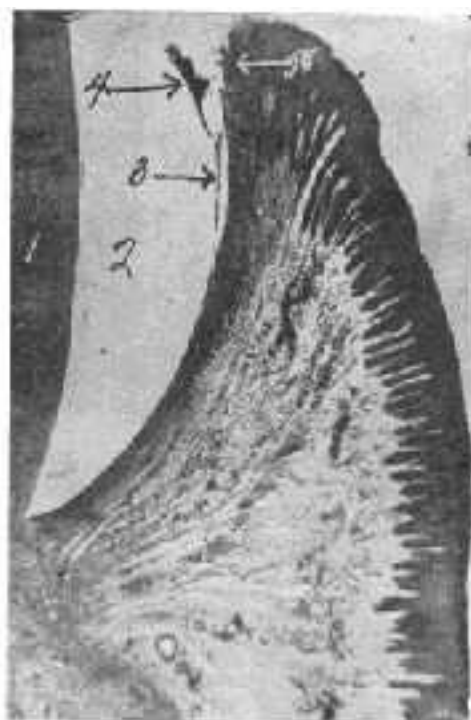
This foreign body effect was recognized and emphasized as the cause of periodontoclasia more than seventy years ago by Dr. John W. Riggs.<sup>16</sup> He supported his claims by the marked benefit and control of the disease he secured by removing this foreign material from the surface of the tooth and polishing it so it no longer caused the constant irritation and suppuration characteristic of the disease. The treatment had to be repeated frequently as the material soon reformed. How different it would have been if he and those who followed him could have had their patients carry out the personal oral hygiene procedure we now know to be possible and essential, thereby preventing the recurrence of the local conditions which originally caused and promoted the disease!

## Material Upon The Tooth And Within The Crevice

In order to devise and adapt personal oral hygiene measures for prevention of the formation of the material upon the tooth which causes and promotes progress of the disease, correct conception of the nature of this material is necessary. We have already seen that the bacterial film (tartar) on the surface of a tooth above the gingival margin at the more protected places where it can accumulate and where it is not dislodged by functional friction (Figures 10,11), consists largely of a thick pad or pile of long rod and filamentous bacteria, one end of which is attached to the enamel cuticle. The other end extends outward to the surface of the film pack where there are usually an abundance of other bacteria of many different kinds.



**Fig. 11. (above)** Proximal of extracted molar stained to show bacterial film. Contact area (1). Heavy bacterial film (2). Epithelial cells remaining attached to tooth (3). Location of cemento-enamel junction (4).



**Fig. 12. (right)** Section through gingival tissue showing foreign material attached to cuticle within the crevice. The early stage of periodontoclasia. Dentin (1). Enamel space (2). Cuticle (3). Bacterial film and concretion on cuticle against which the inflamed free gingiva (5) must rest.

The gingival margin must rest against this bacterial mass of foreign material which causes irritation, inflammation and suppuration. As the foreign material on the tooth builds up and advances into the gingival crevice (Figure 12) the inflammatory exudate there offers favorable environmental conditions and nutritive material for the growth of other types of microorganisms that do not grow outside of the crevice. They are organisms, such as certain leptotrichia, actinomyces, spirochetes, ameba, etc., which prefer or require the more or less anaerobic conditions, inflammatory tissue exudate, blood and pus present in such diseased gingival crevices. After a lesion, although small, is well established at any particular location and any time thereafter during the advancement of the lesion, the surface of the tooth within the crevice against which the inflamed gingival surface rests, has more or less hard calculus on it at most areas. The inner border of such calculus approaches but usually does not quite reach the zone of disintegrating epithelial attachment cuticle,<sup>(1)</sup> a landmark that can be seen on extracted teeth and indicates the exact location of the outer border of the epithelial attachment. Superimposed upon and attached to the calculus and any part of the tooth on which there is none, within the gingival crevice, there is a pad or pile of soft bacterial material. This bacterial film consists largely of closely packed parallel long rod and filamentous forms, one end of which is attached to the calculus or the tooth from which the rod or filament extends outward toward the surface of the pad against which the inner inflamed surface of the gum rests. At the surface of the bacterial film within the crevice there are growing ends and fruiting heads of the rods and filaments composing the pad, and among these more or less other bacteria that invade the lesion from the mouth. Among elements making up the film pad on the tooth within the gingival crevice perhaps the stems and fruiting heads of *Leptothrix falciformis* are the most

noticeable and the most constant. This organism was first described in material from around teeth by Beust(17) in 1906 and 1908. I (5) have called attention to the fact that the habitat of *Endameba buccalis* is among the stems, branches and fruiting heads composing this film pack.


We do not know exactly what role any of the different microorganisms found in the gingival crevice play relative to disease there. Probably it is a very complex process. However it is clear that for the purpose of preventing initiation of the lesions of this disease and preventing further progress of lesions that have already been established, effective measures must be applied to prevent or minimize the growth and accumulation of bacterial material on the tooth at the entrance to, and within, the gingival crevice, which cause the disease (Figures 10, 11, 12).

Food material retained at the entrance to the gingival crevices and between the teeth, and packed into the crevices, promotes growth of bacteria there and increases inflammation of the tissues against which it rests. If food and bacterial material that has accumulated at and within the gingival crevices during the day is effectively removed at night before retiring, there follows a period of many hours during which there is greatly lessened bacterial growth. Rapid subsidence of inflammation occurs. Therefore to effectively prevent the initiation and further progress of periodontoclasia lesions the teeth must be cleaned at and within the gingival crevices every night before retiring. Nothing else will suffice.

## Diagnosis Of Early Stage Periodontoclasia

The periodontoclasia lesion begins at the entrance to and just within the gingival crevice, principally the interproximal crevices, the distal and mesial crevices about teeth where there is no approximating tooth and the crevices at the buccal, labial and lingual embrasures. At first the lesion is only microscopic in extent. Even then there are a few (often only microscopic quantities) pus cells passing through the inflamed inner surface of the free gingiva. These tend to accumulate just within the crevice and at the entrance to it. Material removed from within the crevice by proper technic, stained and examined shows some to many pus cells. There are no pus cells within uninfamed healthy gingival crevices. Therefore, the presence of pus in material from the gingival crevice is diagnostic of inflammation there. Likewise the absence of pus cells means absence of inflammation and absence of periodontoclasia.

Microscopic examination for pus is a very simple procedure. Material must be properly taken from the gingival crevice, spread upon a microscope slide and stained with some one of the many appropriate stains for such specimens. The material must be delicately scraped from within the crevice with an appropriate small instrument. Although some of the instruments usually used by dentists for other purposes may be used, the best results can be obtained with an explorer and scraper which the author first made from a D. C., R & L, Premierlite explorer (Figure 13). The blade is ground to a width of .55 mm. and suitably shaped for entrance and manipulation within the gingival crevices especially the interproximal crevices. A cross section of the blade is half disc shaped. With it one can obtain small amounts of material from the inflamed surface of the gum within the crevice and from the very bottom of the space, where the disease is progressing. Success depends upon correct technic in collecting and preparing material for examination rather than upon collecting large amounts improperly.



**Fig. 13.** Explorer and scraper ("Bass' 55") for exploring, scraping and securing material from gingival crevices and periodontoclasia lesions.

The material is spread in a small area (2 to 5 mm. in diameter is enough) upon a microscope slide. Removal of the small amount of material from the blade of the explorer and spreading it upon the slide can be facilitated by the use of some kind of teasing needle or other small pointed instrument. Several such specimens from different crevices can be placed at different locations on one slide, and all stained and examined at the same time. The author usually mounts on one slide for examination all the specimens taken at a sitting from a given subject.

The slide is ready for staining and examination. Any one of many staining methods may be used satisfactorily. A good one for general purposes is as follows: (1) Fix with heat; (2) Carbol fuchsin one-half minute; (3) Rinse; (4) Crystal violet one-half to one minute; (5) Wash, dry and mount in oil for examination.



Pus and other cells are satisfactorily seen with the low power (16 mm.) objective. Higher powers and the oil immersion objective are needed for study of the bacteria, spirochetes and ameba (*Endameba buccalis*) that may be present.

## Widespread Prevalence of Periodontoclasia

Periodontoclasia is practically a universal disease. There are suppurating lesions about some or all of the teeth of all people except those who have learned and follow the necessary personal oral hygiene to prevent the disease. Anyone who is interested can confirm this by examining, as indicated above, material from his own interproximal gingival crevices, and from those of others.

Inflamed and ulcerated inner surfaces of the free gingiva bleed easily from the slightest force or manipulation. Uninflamed epithelial surfaces do not bleed. Therefore "bleeding gums" can be considered practically diagnostic of inflammation and ulceration—the early stage of periodontoclasia.

In view of the widespread prevalence of this disease it is hardly necessary, for diagnostic purposes, to make microscopic examinations for pyorrhoea, as suggested above. It can be assumed to be present about some of the teeth of practically all adults and most younger people. During a period of several years the author has examined a considerable number of people, mostly medical students and other university personnel. In no instance has he failed to find pus from some of the gingival crevices, and also one or more demonstrable lesions where some receding of the gingival attachment has taken place. This experience, which will be confirmed by those who employ appropriate technic, indicates the extensive prevalence of the disease, the inadequacy of the oral hygiene procedures presently in general use and the need for a better method.

## Necessary Procedure

We may now state the fundamental facts to which the necessary oral hygiene procedure must conform and specify the procedure required. One of these facts is the time honored saying "a clean tooth does not decay." The other, more recent, is "periodontoclasia does not occur about a clean tooth".(8) The author has formulated one sentence which comprehends what every person must know and do to save his teeth from these diseases and to maintain reasonable personal oral cleanliness. It is used as a slogan in teaching personal oral hygiene to others. Anyone who undertakes to teach others how to take care of their teeth (after learning how to take care of his own) will find this sentence of instruction useful and helpful. *"You must clean your teeth right with the right kind of both toothbrush and dental floss every right before retiring."* No part of this sentence may be changed or omitted without impairing its completeness. In the light of present information, no part of these instructions may be disregarded or neglected by anyone except at the jeopardy of his dental health.

All other supposed preventive measures which conflict with, or are intended to supplement, what is comprehended in the above sentence, tend to confuse or detract from the personal oral hygiene that is essential for maintaining oral health and cleanliness. If the teeth are also cleaned partially or well at other times, this contributes to greater oral cleanliness, but under no circumstances may such cleaning at other times of the day take the place of the essential cleaning at night before retiring.


Heretofore the individual has not known exactly how to clean his teeth right and the right kind of toothbrush and dental floss have not been available. Therefore he must be taught by someone who does know.

## Right Kind of Toothbrush

The function of the toothbrush is to dislodge and remove from any and all areas on the teeth that are accessible to the application of the bristles of the brush as much as possible of the decomposing food and bacterial material that has accumulated and is retained there—since the previous cleaning. This material is soft, often microscopic in amount and composed of microscopic particles (bacteria and food elements). Its presence and character can be ascertained only by appropriate microscopic examination. The most important places to be cleaned with the brush are (a) the occlusal pits and fissures, (b) the proximal surfaces in the sulci between teeth as far as the bristles may go and (c) the surfaces of the teeth within the gingival crevices wherever they are accessible to the application of the bristles of the brush.

Material is dislodged and removed by the digging action of the ends of the bristles when the brush is applied firmly against the places to be cleaned and moved back and forth with short strokes ("vibratory motion"). The brush must be pressed down hard enough to force some of the bristles into the pits, fissures, sulci and gingival crevices as far as their diameter will allow them to go. The bristles must be flexible enough to allow those that do not enter the deeper spaces at the moment, to be deflected and not prevent others from entering. They also must be flexible enough so they bend and do not injure the gingival tissue when applied directly to the gingival crevices, and manipulated so as to secure the necessary digging action to dislodge the foreign material on the tooth within the crevice. For the same reason the ends of the bristles must be round and smooth instead of sharp, jagged, chisel shaped and rough, as the bristles of so many current toothbrushes are (Figure 14). The shape, size and form of the


brush must be such as to adapt it to the most practical and effective application and manipulation for the purpose for which it is used (Figure 15).



**Fig. 14.** Selected .014" bristles (left) from current toothbrush by the side of .007" bristles with smoothed and rounded ends from right kind brush.


**The specifications for the right kind of toothbrush are:**

1. Plain straight-handle design; over-all length about 6", width about  $\frac{7}{16}$ "; 3 rows of bristles, 6 tufts to the row, evenly spaced (Figure 16) .
2. High quality nylon bristles, about 80 per tuft, .007" diameter, straight trim, finished to  $\frac{13}{32}$ " length.
3. Ends of bristles ground and finished to hemispherical shape or at least so as to eliminate all sharp points and rough edges.
4. A similar brush of reduced size for the use of young children should have an overall length of about 5", .005" bristles, finished to  $\frac{11}{32}$ " length.



**Fig. 15.** Right kind toothbrush referred to in this paper and described elsewhere (3). Note straight handle and construction and straight trim.

Based upon much study of the spaces to be cleaned, the character of the material to be removed, and the conditions to be met, the author has specified elsewhere (3) the optimum characteristic of toothbrushes for personal oral hygiene, giving the reason for each of the characteristics specified. The specifications laid down meet the requirements indicated above. This, and no other, is the right kind of toothbrush. In the light of present information any brush that deviates from the characteristics specified is less effective and less appropriate for the purpose, to the extent it so deviates.



**Fig. 16.** Face view of right kind toothbrush, showing distribution of tufts.

## Brushing The Teeth

All the surfaces of all the teeth to which the brush can be applied, should be brushed. A good system is to brush the buccal and labial surfaces of all teeth first, then the occlusal and lingual surfaces of the grinders in all four quadrants and finally the lingual surfaces of the anterior teeth. The bristles of the heel of the brush can be applied most effectively to the lingual surfaces and the gingival crevices of these latter teeth. The bristles of the distal end or toe of this right kind of brush can be applied most effectively back of the last tooth in each quadrant by tilting the brush for this purpose at the same time the occlusal and lingual surfaces of the grinders are brushed. Anyone should be able to brush all of these teeth well enough for all purposes in less than one minute.

## Dentifrices

The question of denitrifies necessarily arises. If one's hands are soiled with food and other objectionable material, he washes them with soap and water. A touch of soap (toilet soap) on the brush helps to clean similar material from the teeth. Nothing else is necessary for routine purposes.

The teeth of many people become stained with various substances such as tobacco, tar, certain stains in food and beverages, sometimes stains produced by chromogenic bacteria. Such stains are retained by the bacterial film but do not pass through it into the tooth. They may be removed and minimized by a mildly abrasive powder on the brush. Ordinary prepared chalk is effective. When used with the right kind of brush here suggested, it is harmless. It may be used as frequently as the individual requires. The teeth of some individuals stain much worse and in shorter time than others. Each person should use prepared chalk as often as necessary to prevent objectionable discoloration of his teeth. Some will require it every day, others only once in several days or longer.

The sweetening and strong mint or other flavors which most dentifrice's contain serve no useful purpose and are more or less harmful.

## Cleaning The Proximal Surfaces

No matter how much or what kind of brushing is done, it is not possible for the bristles to reach and clean the proximal surfaces between the teeth. It is simply imagination to think otherwise. At the contact point the teeth are in direct contact and there is no space between them. For a variable distance extending outward from the contact plane in all directions there is a gradually widening space which is filled with a pack of bacteria, mostly long rod and filamentous type. This material has the form of a somewhat irregularly outlined biconcave disc (Figure 10) with the center corresponding to the contact point. When heavily inoculated food material is lodged upon the outer part of this biconcave disc where there are large numbers of growing ends and fruiting heads of the rods and filaments of which it is composed, acids may be produced there and may be carried, as if by a sponge or wick, deeper into the space. If the acid production continues long enough, ultimately there is partial decalcification—early stage caries—and later perhaps breaking down, cavity formation—advanced stage caries. In order to surely prevent these events it is absolutely necessary to clean the proximal surfaces of the teeth in this area every night before retiring. When done right this removes most of the bacteria and the food material in which they could grow and produce acids. There is not sufficient time from the time food is put in again the next day, for maximum growth of bacteria and for production of harmful amounts of acid, before time to clean the teeth again at night before retiring.

The only way now known, and the only way likely to ever be known, whereby the bacterial film on the proximal sides of the teeth can be removed is by the proper use of the right kind of dental floss. Elsewhere (4) the author has specified the optimum characteristics of dental floss for personal oral hygiene, indicating the necessity or basis for each characteristic specified. This right kind of dental floss consists of 170 very fine filaments of high tenacity nylon. It is not waxed, and is only slightly twisted (3 turns to the inch). When drawn across the surface of the tooth, each of the 170 separate filaments is potentially capable of mechanically dislodging and removing some part of the microscopic bacterial material thereon. Also the bundle of loosely held together filaments is capable of receiving and holding in the spaces between the filaments (Figure 17), large numbers of microscopic particles (bacteria).



**Fig. 17.** Less than one-third the total number of nylon filaments contained in the right kind dental floss. Each separate filament, when properly used, is potentially capable of scraping off or dislodging some material and the many spaces between them can hold many microscopic particles, bacteria, etc.

## Necessity For Cleaning The Tooth Within The Interproximal Gingival Crevices

So far as proximal caries of the enamel is concerned, it is only necessary to clean the proximal surfaces of the tooth above the gingival margin or the papilla. We have seen that from the very earliest stage of periodontoclasia there is bacterial film and other foreign material on the surface of the tooth within the gingival crevice (Figure 12) and that this material is responsible for the initiation of the very earliest lesion and for the continued progress of the disease. To prevent the beginning and progress of the inflammation and

suppuration which characterizes the disease it is necessary to clean these areas of the teeth within the crevices. This can be done well enough with the right kind of dental floss mentioned above but it cannot be done in any other practical way now known. The surfaces of all teeth within the interproximal crevices of contacting teeth, and those within the distal or mesial crevices where there are no contacts, must be cleaned. This is accomplished by carrying the floss down to the very bottom of the crevice, holding it against the tooth and drawing it slightly endways and outward so as to scrape the surface. The bacterial material is dislodged and much of it is held and removed within the spaces between and around the filaments (Figure 17) of the floss.

## Detailed Directions For Cleaning The Teeth Right With The Right Kind Of Dental Floss

While different people may develop their own technic and manipulations for cleaning their teeth with dental floss, the following procedure is probably the most practical and effective:

1. Cut off a piece of floss about 2 to 3 feet long.

2. Wrap one end with 2 or 3 turns around the first phalanx of the right index finger, for the purpose of anchoring or holding it. ( Figure 18 )

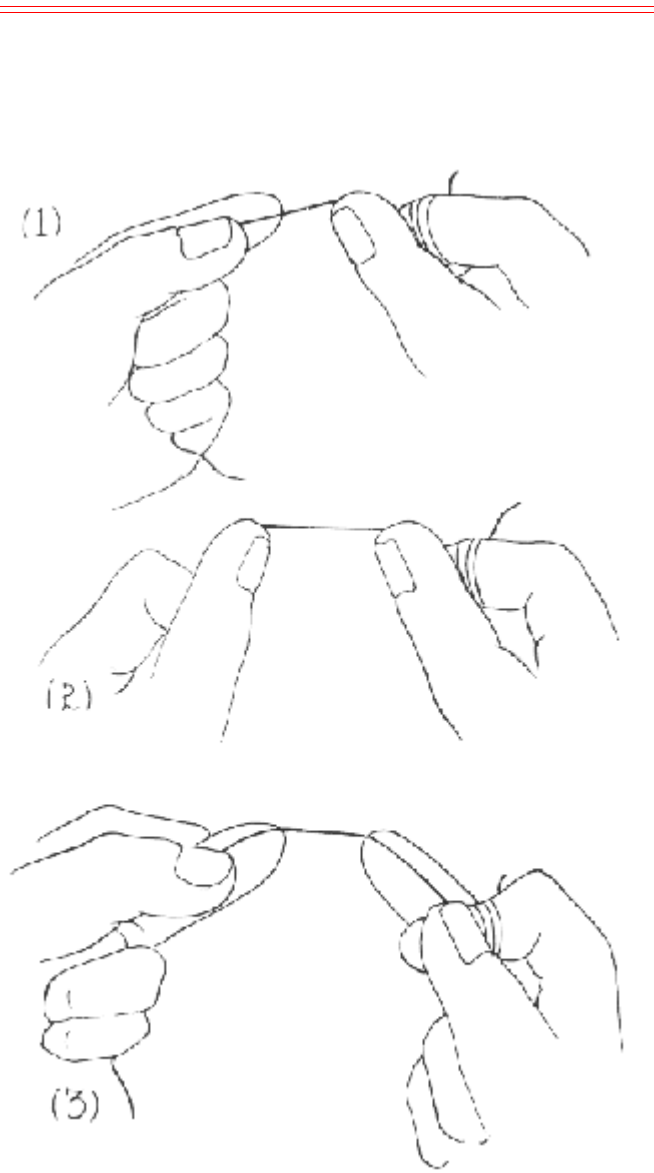
3. Bring the floss over the end of the right thumb which is also held against the finger around which the floss is anchored. (Figure 18).

4. Grasp the floss with the left hand and bring it over the end of the first finger of that hand. Thus a length of floss, about 1 inch long, is held between the thumb of the right hand and the first finger of the left hand. (Figure 18 ( 1 ) ).

5. Now with the thumb inside of the cheek and the finger inside of the mouth, the floss is carried to the very bottom of the gingival crevice back of the last right upper tooth, drawn slightly endways through the crevice and crossways outward across the distal surface so as to scrape off and dislodge the soft bacterial material on the tooth within the crevice and outwards.

6. Holding the floss in the same way, pass it into the next interproximal space. Carry it to the bottom of the posterior gingival crevice and clean the mesial surface of that tooth. Now, before withdrawing the floss from this interproximal space, clean the distal surface of the other tooth in the same way. Then withdraw the floss and move on to the next interproximal space, etc., until the proximal surfaces of all teeth have been cleaned.

7. In passing the floss between contacting teeth it is not forced directly in and out. It should be held over the contact and drawn gently and slightly back and forth endways. This allows the low-twist, unwaxed floss to flatten and pass between the contacting teeth with the greatest ease.



**Fig. 18.** Best way to hold floss in cleaning the teeth. For upper right (1). For upper left (2). For lowers (3).

8. After cleaning 2 or 3 teeth the part of the floss used is somewhat soiled and loaded with bacterial material. It is desirable to move along the string to a new place by taking another turn around the anchoring finger. This should be repeated from time to time as needed.

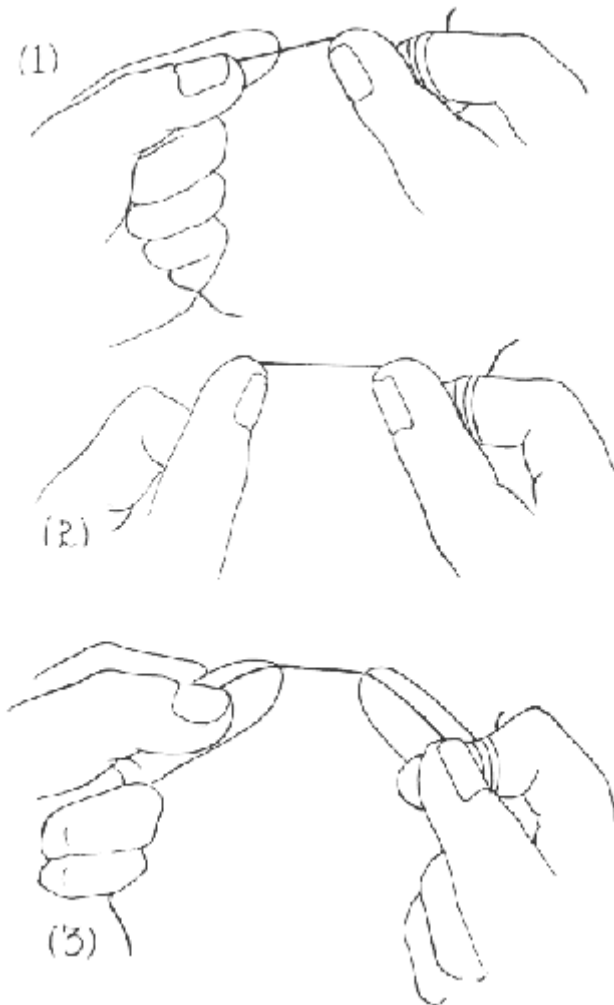
9. The floss is held and manipulated with the same fingers as indicated above until after the surfaces of the teeth in the interproximal space between the left central and lateral have been cleaned.

10. In cleaning the rest of the upper teeth, it will now be found more convenient and practical to hold the floss over the ends of the thumb of the right hand as before and over the thumb (instead of the index finger) of the left hand. (Figure 18 (2)).

11. All the lower teeth now should be cleaned in the same way. Most people will find that they can carry out the necessary manipulations most successfully with the floss held over the ends of the second finger of each hand instead of the thumbs or the thumb and first finger as in cleaning the upper teeth. (Figure 18 (3)).

12. After cleaning all the teeth with dental floss, the mouth should be thoroughly rinsed by forcing water vigorously back and forth between the teeth in order to remove material that has been loosened or dislodged but not removed by the floss. After a little experience one can clean all his teeth well with dental floss in from 2 to 3 minutes.

13. It gives a pleasurable sensation of cleanliness to hastily brush the teeth again after cleaning them with dental floss. But this is not essential.



**Fig. 18.** Best way to hold floss in cleaning the teeth. For upper right (1). For upper left (2). For lowers (3).

## Results

The author has instructed and had under observation, a sufficient number of subjects to be able to state positively the beneficial effects that result from the personal oral hygiene herein specified.

1. No new caries lesions develop.

2. Early stage lesions (mostly unrecognized "white spot" partially decalcified enamel that has not broken down) do not progress further or break down.
3. Small shallow cavities do not progress but usually become inactive.
4. Correctly made fillings do not undermine or break down.
5. No new periodontoclasia lesions occur.
6. All early stage periodontoclasia lesions heal promptly. It is almost dramatic the way in which the bleeding from the gingival crevices stops entirely after the first few days. Pus (even microscopic quantities) is no longer present in material from most of the crevices, and greatly diminished in that from others. The delayed or incomplete healing in such lesions is usually due either to calculus or scale on the tooth within the crevice or to irregularities or other conditions on the surface of the tooth which prevent accurate application of the floss. In most such instances, removal of the foreign material from the surface of the tooth at, and within, the gingival crevice by the dentist, followed by the right personal oral hygiene, results in prompt subsidence of the disease.
7. Each advanced stage periodontoclasia lesion and deep "pyorrhoea pocket" is a separate problem. However, cleaning off the tooth at and within the lesion by the dentist at suitable intervals together with faithful application of the personal oral hygiene described herein usually will yield most gratifying results. The beneficial results will depend largely upon the extent of the lesion and the damage already done. In favorable instances suppuration and inflammation of periodontal tissues subside, and loose, drifting teeth usually stabilize.
8. Foul odors from the mouth due to decomposition of food material about the teeth, to putrefaction of inflammatory tissue exudates within the crevices and to the growth of certain microorganisms (especially spirochetes) in the blood enriched material in the crevices, is avoided.
9. Much satisfaction is derived from the sense of oral cleanliness which one enjoys, after he once understands the conditions and learns how to clean his teeth effectively.

## Comment

Every person who has teeth to save and everyone who desires to maintain reasonable oral cleanliness must learn and follow the personal oral hygiene procedure herein described. People go to dentists for treatment of the advanced stage of caries and periodontoclasia from which nearly all loss of teeth results. They do not know or properly evaluate the fact that the lesions, representing more or less irreparable damage, could have been prevented. Neither do they recognize the presence of existing earlier stage lesions, further progress of which can be prevented by personal oral hygiene. They need to be instructed.

Dentists should be interested in teaching this necessary personal oral hygiene to their patients not only for the purpose of prevention but also to greatly improve the success and durability of their treatment of existing lesions and conditions. To fill a cavity without making certain, at the same time, that the patient knows how to maintain the necessary cleanliness of the area in the future reduces, on the average, the usefulness and success of the work done. To clean the accumulations of foreign material from the teeth or to treat his periodontoclasia without, at the same time, teaching the patient how to keep his teeth clean in the future, greatly reduces the value of the service. The value of the periodical visit to the dentist for check up and "prophylaxis" is very greatly increased if the patient is also taught this necessary personal oral hygiene.

It is evident that the practicing dentist should teach the necessary personal oral hygiene to his own patients. However, to teach it he must first know it himself. It is axiomatic that one cannot teach what he does not know himself. Except for anyone who may have already learned how to clean his teeth right, as here indicated, the dentist who still has teeth left now has more or less suppuration within the gingival crevices, and therefore active periodontoclasia, about some or many of his teeth. This will be confirmed by microscopic examination of properly collected material from his interproximal gingival crevices. He is losing his own teeth from the same conditions for which his patients need advice and treatment. Until he learns and practices the necessary personal oral hygiene to save his own teeth, he is not very well prepared to instruct his patients how to save theirs. Therefore he should first learn and practice the right method himself. Then he will realize how necessary it is for his patients also and can instruct them correctly and effectively.

## Summary

The necessary personal oral hygiene for prevention of caries and periodontoclasia has been presented in some detail. It conforms to the two fundamental facts: "a clean tooth does not decay" and "periodontoclasia does not occur about a clean tooth." The essentials are embraced in the teaching slogan which the author has formulated, uses, and recommends that others use: ***You must clean your teeth right with the right kind of both toothbrush and dental floss every night before retiring.***

## References

1. Bass, C.C.: A demonstrable line on extracted teeth indicating the location of the outer border of the epithelial attachment. *J. Dent. Research*, 25:401. 1947.
2. Bass, C.C.: The enamel cuticle. I, in relation to the early stage of caries; II, in relation to the early stage of periodontoclasia. To be published soon.
3. Bass, C.C.: The optimum characteristics of toothbrushes for personal oral hygiene. *Dent. Items Int.* 70 :697, 1948
4. Bass, C.C.: The optimum characteristics of dental floss for personal oral hygiene. *Dent. Items Int.* 70: Sept., 1948.
5. Bass, C.C.: The habitat of *Endameba buccalis* in the lesions of periodontoclasia. *Proc. Soc. Imp. Biol. and Med.* 61:9. 1947.
6. Frisbie, H. E., Nuckolls, J. and Saunders, J. B.: Distribution of the organic matrix of the enamel in the human